

Linda E. Norton,¹ M.D.; James A Cottone,² D.M.D., M.S.;
Irvin M. Sopher,³ D.D.S., M.D.; and Vincent J. M. DiMaio,⁴ M.D.

The Exhumation and Identification of Lee Harvey Oswald

REFERENCE: Norton, L. E., Cottone, J. A., Sopher, I. M., and DiMaio, V. J. M., "The Exhumation and Identification of Lee Harvey Oswald," *Journal of Forensic Sciences*, JFSCA, Vol. 29, No. 1, Jan. 1984, pp. 19-38.

ABSTRACT: The investigations surrounding the assassination of President John F. Kennedy and the subsequent killing of Lee Harvey Oswald resulted in many theories concerning what really happened in November 1963. One theory postulated the substitution of a Russian agent for Oswald; another that his grave was actually empty. This report documents the historical background, legal proceedings, preparations and actual exhumation, examination, and identification of the remains of Lee Harvey Oswald. The pertinent findings of a cracked vault, deteriorated casket, decomposed remains, two rings, a mastoidectomy defect, and the details of the positive dental identification are presented. Additional items covered include team formation, security measures, site selection, financial considerations, the news media, and selection of authorized witnesses.

KEYWORDS: pathology and biology, odontology, Lee Harvey Oswald, human identification, dentition

Historical Background and Legal Proceedings

Lee Harvey Oswald was born on 18 Oct. 1939 in New Orleans, LA (Table 1). He was a member of the United States Marine Corps from 24 Oct. 1956 through 3 Sept. 1959. Following his release from active military duty, Oswald defected to the USSR, met and married Marina Prusakova, a Russian citizen, and together, they returned to the United States in 1962.

On 22 Nov. 1963, President John F. Kennedy was assassinated in Dallas, TX. Oswald was arrested in connection with the assassination and two days later, was fatally shot by Jack Ruby while being transferred to a vehicle at the Dallas County Jail. An autopsy was performed by Dallas County Coroner Dr. Earl Rose. Although Oswald's identity was not in question at the time, a single thumbprint was taken that was positively compared with military records.

Fourteen years later, British author Michael Eddowes published *The Oswald File [1]* in which he alleged that a "look-alike" Russian agent had been substituted for Oswald during his defection and returned to the United States to assassinate President Kennedy. Using what Eddowes called "inconsistencies" between Oswald's Marine Corps medical records and the autopsy

¹Medicolegal consultant, Dallas, TX.

²Associate professor and head, Section of Forensic Odontology, Department of Dental Diagnostic Science, The University of Texas Health Science Center at San Antonio Dental School.

³Chief medical examiner, State of West Virginia, South Charleston, WV and clinical professor of pathology, West Virginia University School of Medicine and Marshall University School of Medicine.

⁴Bexar county chief medical examiner, San Antonio, TX.

TABLE 1—*Lee Harvey Oswald—historical background and legal proceedings.*

Date	Occurrence
18 Oct. 1939	Date of birth
24 Oct. 1956	Induction into U.S. Marine Corps
3 Sept. 1959	Separation from U.S. Marine Corps
1961	Oswald marries
13 June 1962	Oswald returns to United States
22 Nov. 1963	President John F. Kennedy assassinated
24 Nov. 1963	Oswald assassinated
1977	Eddowes publishes <i>The Oswald File</i>
10 Jan. 1979	Eddowes files suit to force exhumation
1 June 1979	Eddowes' request denied
Aug. 1979	Attorneys for Eddowes approach Dallas County medical examiner
30 Aug. 1979	Dallas medical examiner obtains medical and dental records
Sept. 1979–Feb. 1980	Jurisdictional battle between Dallas and Tarrant Counties
20 Feb. 1980	Tarrant County withdraws active opposition to exhumation
21 Feb. 1980	Dallas medical examiner withdraws saying exhumation unnecessary
8 Aug. 1980	Marina signs autopsy consent
14 Aug. 1980	Robert Oswald obtains Temporary Restraining Order (TRO) against exhumation
5 Sept. 1980	Robert's injunction granted
19 Aug. 1981	Marina files suit against Robert
17 Sept. 1981	The Court of Appeals dissolves Robert's original injunction
23 Sept. 1981	Robert Oswald granted TRO
25 Sept. 1981	Robert capitulates
Midnight, 3 Oct. 1981	TRO expires
4 Oct. 1981	Exhumation and identification occurs

report, he first approached Dr. Felix Gwozdz, then Medical Examiner for Tarrant County, Texas (Fort Worth), where Oswald was buried, requesting that he exhume the body so as to verify the identification.

When Dr. Gwozdz refused, Eddowes filed suit in the Tarrant County 141st District Court against both Dr. Gwozdz and the Tarrant County District Attorney to force exhumation [2]. The court granted a summary judgment for the defendants denying Eddowes request. The Texas Court of Appeals later stated that the trial court should have dismissed the case, an opinion which was upheld by the Texas Supreme Court.

Meanwhile, while awaiting appeal, attorneys for Eddowes approached Dr. Linda Norton, then Medical Examiner for Dallas County, suggesting that the Dallas County Medical Examiner's Office resume their original jurisdiction over the case and exhume the body. After consulting with Dr. Charles Petty, Dallas County Chief Medical Examiner, Dr. Norton obtained a copy of Oswald's medical and dental records including dental interproximal ("bitewing") radiographs from the Military Personnel Records Center in St. Louis, MO. These records would be useful for a forensic science identification because they were dated before Oswald's defection to the USSR and thus contained identity data of the "real" Lee Harvey Oswald. Dr. Petty subsequently requested that the pathology resident who had recently replaced the deceased Dr. Gwozdz as Tarrant County Medical Examiner exhume the body "buried in Rosehill Cemetery under the name of Lee Harvey Oswald" under Article 49.25 of the Texas Code of Criminal Procedure and send the remains to the Dallas County Medical Examiner's Office for autopsy. A jurisdictional battle ensued as legal opinions regarding Article 49.25 varied considerably as to which county, if any, had jurisdiction over a person killed in one county but subsequently buried in another. The conflict appeared to be resolved some six months later when Tarrant County officials withdrew their active opposition to the exhumation, clearing the way for Dallas County to proceed; however, the Dallas County Chief Medical Examiner then also withdrew stating that he no longer felt the exhumation was necessary. At this point, all legal actions had been completed and all involved parties were quiet for several months.

Eddowes then directed his attention to Marina Oswald Porter, Oswald's legal next of kin, and obtained her signature on a consent for Dr. Petty to perform the autopsy at the Dallas County Medical Examiner's Office as a "private case." Eddowes was to pay all expenses. News of the preparation for exhumation prompted Oswald's brother, Robert, to request a temporary restraining order (TRO) which was granted by the aforementioned 141st District Court. In his original petition, Robert Oswald named Petty, Eddowes, Marina Oswald Porter, Rosehill Cemetery, and the Dallas County Commissioner's Court Judge. By amended pleadings, Robert dismissed all but Petty, Eddowes, and Rosehill Cemetery. The court denied the injunction against Rosehill Cemetery, granted Petty the right to be sued in the county of his residence, rather than Tarrant County (thus, effectively severing him from the suit), and granted Robert's injunction against Michael Eddowes. Petty failed to comply to a subpoena to appear for the hearing (because of miscommunication) and Robert's attorneys filed a motion for contempt. Meanwhile, the Dallas County Commissioners, stirred by what they considered "adverse publicity" for Dallas County, openly opposed the use of any county facility for the examination, justifying their position by stating that a "private" autopsy should not be performed using county property.

During the next year, while awaiting Eddowes' appeal of the injunction, numerous negotiation attempts, motions, and counter motions kept attorneys for all sides occupied. Finally, on 19 Aug. 1981, Marina, tiring of the harassment and believing that the grave was in fact empty, filed suit against Robert. By remarkable coincidence the case became "randomly" assigned to the 141st District Court.

On 17 Sept. 1981, slightly over a year after the lower court's decision to grant Robert Oswald an injunction against Eddowes, the Court of Appeals heard the case. Again, they reversed the 141st District Court citing Article 49.05 of the Texas Code of Criminal Procedure. The court found that Robert had no "justiciable" interest in the exhumation of the remains of his brother given the fact that there was a surviving spouse and children. Marina Oswald Porter was now considered by the Court of Appeals as an "indispensible party" because of her statutory rights under Article 49.05. By dissolving the injunction, the court effectively allowed Marina to pursue her lawsuit against Robert.

Despite the higher court's decision, a week later the 141st District Court again granted Robert a temporary restraining order against Marina; however, Robert and his attorneys capitulated citing emotional and financial burdens as the reason. Thus, the temporary restraining order was allowed to run its ten-day course and expire at midnight, 3 Oct. 1981, permitting Marina without judicial intervention, to proceed with the exhumation on 4 Oct.

Preparations for Exhumation and Examination

As litigation progressed and it became apparent that the exhumation would ultimately take place, practical issues were addressed by attorneys for both Eddowes and Marina. The choice of Dr. Norton as the chief forensic pathologist for the examination was based on the fact that: (1) she was familiar to the attorneys; (2) she had escaped involvement in any of the litigation; and (3) she had possession of the critical medical and dental records and radiographs. Because of the legal implications of the case, a team approach was elected, with the desired goal to keep the team as small as possible. A total of two forensic pathologists and two forensic odontologists was felt to be sufficient.

The selection of an examination site was more difficult. The county commissioners had earlier denied the use of the Dallas Institute of Forensic Science, and Mrs. Marina Oswald Porter refused to allow the remains to be transported out of the Dallas-Fort Worth area. Therefore, a search was conducted for a local facility that: (1) could be effectively secured and (2) whose personnel were willing to accept the certain disruption of routine and possible controversy to be expected in a case of this nature. Dr. George Race, Chairman of the Department of Pathology at Baylor Hospital in Dallas, was approached and, with the consent of Baylor Hospital ad-

ministrators, agreed to the use of his facility. Dr. Cottone, team member and forensic odontologist at the University of Texas Health Science Center at San Antonio, with the permission of health science center administrators, supplied the necessary equipment for the dental examination. Mr. Eddowes was responsible for all expenses. The examination team worked for expenses only because of the controversial nature of the case; Baylor accepted a very nominal fee; and at least one attorney, to date, has received no remuneration.

The autopsy facility at Baylor satisfied all requirements for a secure examination. Once access to the autopsy area was achieved, minimal security was necessary to prevent any trespass caused by a single door entry (Fig. 1). Security was of paramount importance, especially to

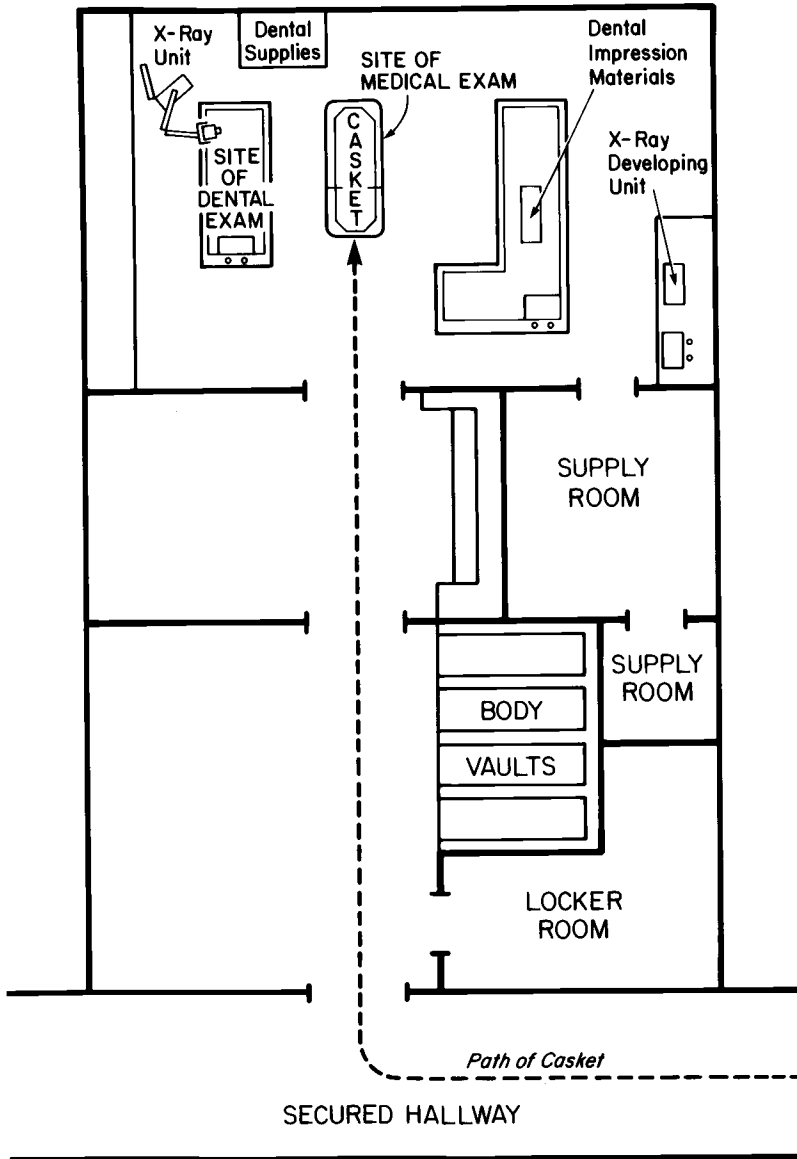


FIG. 1—Baylor Pathology Laboratories (schematic drawing) as equipped, staffed, and used for the examination and identification of Lee Harvey Oswald on 4 Oct. 1981.

Mrs. Marina Oswald Porter, who abhorred the idea of the possible publication of another unauthorized photograph of Oswald's remains as had occurred subsequent to the 1963 autopsy. The examination team was allowed to make only close-up documentary photographs as shown herein. The entire proceeding was, however, videotaped by a personal friend of the Porters. Security was handled by a private agency, as chosen by the attorneys.

Other persons allowed to be present during the examination were determined largely by the various attorneys. The examination team was assisted by one pathology technician and one dental radiology technician. Dr. Race and his chief associate alternated to help maximize the use of their equipment and facility; a court recorder noted all proceedings; and attorneys representing Eddowes, Marina Porter, Robert Oswald, and Rosehill Cemetery, were also present. The mortician who closed Mr. Oswald's casket remained in the room until the casket was reopened.

Members of the news media were totally excluded from the proceedings with the exception of one United Press International (UPI) reporter who, upon agreement with at least one of the attorneys, was allowed into a morgue anteroom. A single public press conference was held at the conclusion of the examination, coincidental with the body being transported back to Rosehill Cemetery for reinterment in a new casket and vault.

The Exhumation

A small crowd gathered at Rosehill Cemetery during the predawn hours of Sunday, 4 Oct. 1981 (Table 2). Backhoes began work on the gravesite as soon as there was sufficient light for safe operation. Speedy removal of the remains was emphasized: (1) for better security and (2) to allow the cemetery to open its gates for gravesite visitations as early as possible. The concrete vault was quickly exposed and noted to be cracked which negated the original plan to remove and transport it intact for opening at the vault company. A trench was dug along the vault which allowed workmen to open it easily. Extensive water damage to the casket was apparent: the cover was weak in many areas, and in one place had caved in partially exposing the remains.

A wooden platform was lowered into the trench and the casket was gently slid onto it. A cardboard lid, designed to fit over the casket, was in place before lifting the platform from the grave and placing it in a hearse. The entire operation was completed by 9:00 a.m. (Central Daylight Savings Time [CDT]), by which time, a large crowd of spectators and news media representatives had gathered. The hearse, heading toward Dallas, lent further credence to the assumption that the examination was to take place at the Dallas Institute of Forensic Science. Thus, most of the news media went to that office which facilitated the rapid transport of the casket into the Baylor autopsy area (Fig. 1).

TABLE 2—*Timetable of exhumation and identification of Lee Harvey Oswald, 4 Oct. 1981.*

6:30 a.m. ^a	Exhumation began
8:00 a.m.	Unearth casket
9:00 a.m.	Leave Rosehill
9:20 a.m.	Arrive at Baylor Medical Center, Dallas
2:30 p.m.	Exam complete
3:00 p.m.	News conference
4:00 p.m.	Reinterment

^a Central Daylight Savings Time.

The Forensic Science Examination

Decedent: Oswald, Lee Harvey.

Date of examination: 4 Oct. 1981.

Place of examination: Baylor Medical Center, Dallas, TX.

Time of examination: 10:00 a.m. (CDT).

External Examination

The remains were received in a moderately rotting wood coffin measuring 203 cm (80 in.) in length with a depth of 61 cm (24 in.) and an estimated width of 61 cm (24 in.) with the thickness of the casket sides being approximately 2.5 cm (1 in.).⁵ The exterior aspects of the coffin showed moisture softening of the wood and a diffuse dark brown-black splotchy discoloration with several markedly tarnished apparent metallic ornaments noted about the sides. The above measurements do not include the wooden top of the casket which dismembered upon removal from the casket itself.

The interior of the casket showed similar splotchy brown-black discoloration and moisture-softening of the wood texture. A portion of fabric mesh material, representing remnants of the fabric lining of the top of the casket, had fallen upon the decomposed remains covering the anterior torso area. This was removed to reveal a clothed markedly decomposed body lying on its back upon the casket floor, lower extremities extended and straight with the upper extremities flexed at the elbow and with the hands resting upon the anterior abdomen at the approximate level of the waist. The skull faced anteriorly. The body rested upon a straw mat bedding material, markedly rotten, which currently possessed a thickness of approximately 2.5 cm (1 in.).

The clothing upon the body showed variable degrees of disintegration caused by postmortem change. The clothing was in normal position upon the remains with the outer layer of clothing consisting of relatively intact coarse-woven dark (dark-brown) suit coat and matching trousers secured about the waist by elastic band rather than belt. Few remnants of a disintegrated light-colored shirt were identified and a relatively intact black standard necktie was in usual position within the anterior torso midline and about the neck. A relatively intact pair of white with green diamond pattern boxer undershorts were also in position upon the body in addition to dark socks upon the feet; shoes or remnants thereof were not identified within the casket. The body, with the exception of the skull, as will be described, was not removed from the casket nor was it dislodged, therefore, the posterior aspects of the clothing and body were not examined. None of the clothing was incised or removed from the body.

Upon entry into the casket a moderate malodor emanated from the decomposing body. As measured in the casket from superior skull to heel region on the left, a body length of 177 cm (69½ in.) was obtained. A gold wedding band and a red stone ring were removed from the fifth digit of the left hand (subsequently identified by Mrs. Porter as representative of items placed upon the body at the time of initial burial). The head structures will be described below. The clothing present upon the anterior torso was displaced laterally revealing diffusely decomposed markedly shriveled and shrunken friable soft tissue which, where remaining, showed primarily saponification and adipocere formation with a pair of postmortem tissue disintegration defects noted within the bilateral pectoral chest areas measuring 15.25 cm (6 in.) on the left and 10.2 cm (4 in.) on the right. The remaining anterolateral ribs were markedly friable and crumbled with mild pressure. The majority of the soft tissue of the anteroabdominal wall was totally disintegrated and contained within the body cavity was a beige plastic bag measuring 69 by 50 cm (27 by 19½ in.) with an approximate 28 cm (11-in.) diameter which contained a minimal amount of pasty tan decomposed tissue estimated at 20 cm³. The existing thoracoabdominal cavity was limited posteriorly by brown-black friable decomposed soft tissue as described for the anterior torso. Embalmer stuffing material filled the body cavity. The exposed feet showed partial skeletoniza-

⁵The original measurements were made in inch-pound units.

tion. The skin covering the lower extremities was markedly shriveled with marked dissolution of subcutaneous soft tissue and muscle so that the present diameter of the lower extremities was estimated at approximately one third of the in life circumference. The intact skin upon the distal lower extremities had a friable consistency, was more dry than wet, shriveled, and parchment-like. The length of the right tibia as the body existed within the casket was 38 cm (15 in.). (According to Trotter-Gleser data for white males, the estimated stature is 174 cm (5 ft 8½ in.))

The body as existed in the coffin showed no evidence of mutilation other than postmortem disintegration; the same statement applied to the remaining clothing. Patchy areas of variable-colored mold formation were also noted about the body exterior. The body was maintained in anatomic continuity by virtue of decomposed soft tissue. The remains and casket were devoid of maggots with few crawling insect forms noted.

The head was removed from the remainder of the body by incision of the mummified soft tissue maintaining the skull, cervical and thoracic vertebral column in normal continuity. This incision was made at the approximate second cervical vertebral interspace. The skull was covered by patchy areas of both mummified soft tissue as well as adipocere formation. The calvarium for the most part was free of soft tissue, however, a few strands of approximate 10 cm (4 in.) in length straight dark brown-black scalp hair were noted embedded within mummified scalp soft tissue adjacent to the right frontal scalp. A previous autopsy saw cut in the usual fashion was present on the calvarium with an anterior inverted V-notch in the right frontal region. The calvarium was maintained in continuity with the remainder of the skull by virtue of decomposed mummified tissue. The previously sawed calvarium was not separated nor was it easily dislodged. The interior of the skull was not examined. The supraorbital ridges of the skull were male in character and the nasal aperture was slightly ovoid with a sharp inferior sill. The mastoid prominence of the left temporal bone revealed an irregularly ovoid 1.0- by 0.5-cm defect penetrating to the interior of the mastoid bone with the defect edges rounded and smooth (Fig. 2). The mandible was maintained in anatomic continuity with the skull by virtue of decomposed soft tissue at the areas of articulation with the skull and by an embalmer wire perforating the maxillary and mandibular anterior jaw structures. This wire was cut and the mandible was readily disarticulated from the base of the skull so as to enable postmortem dental examination.

No incisions upon the body were made except for that necessary for removal of the skull from the vertebral column and for subsequent disarticulation of the mandible and exposure of the dentition. Because of the friable condition of the body it was elected to remove the skull only from the casket with minimal disarticulation of the remains in accordance with the desires of next of kin. The above examination was performed with the remains within the casket and without removal. Only manual manipulation of the remains was used so as to afford the observations noted above. No histologic sections nor toxicologic specimens were retained.

Dental Examination

Initial cleansing of the teeth was followed by a series of radiographs and photographs to document the status of the dentition before any further disruption. After the mandible (Fig. 3) was disarticulated from the maxilla (Fig. 4), they were further cleansed, photographed (Fig. 5), radiographed (Figs. 6 and 7), and the complete dentition independently charted by each forensic odontologist. Dental study casts were also made (Fig. 8). The complete postmortem charting is in Fig. 9 with a comparison to the antemortem records in Table 3.

Dental Comparison

It was necessary to answer two questions concerning the dental records prior to the disinterment. The first question was that of the date of the dental interproximal radiographs (Figs. 6 and 7) which Dr. Norton had obtained. From the list of Available Antemortem Dental Records (Table 4), it is noted that Oswald's initial dental health record was completed at Marine Corps

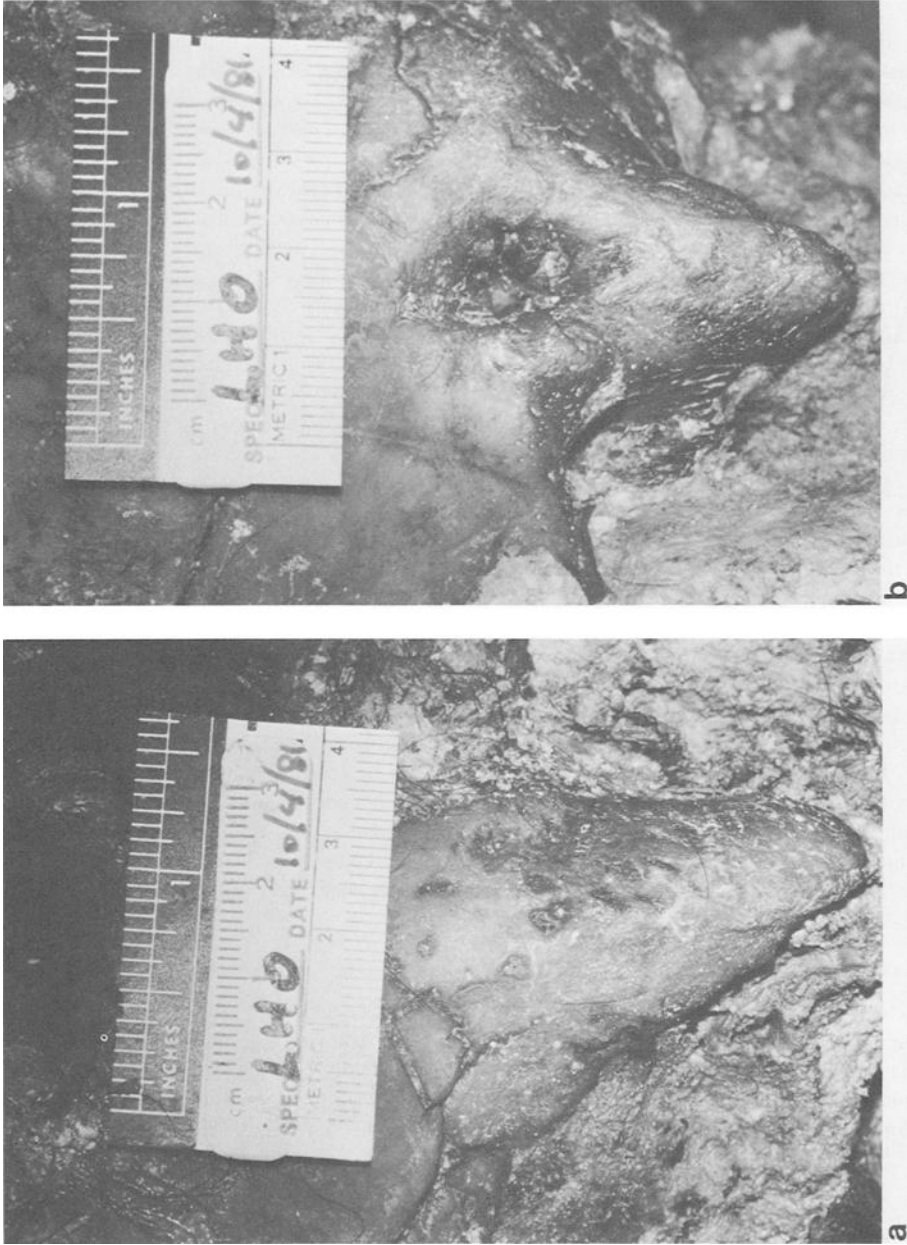


FIG. 2.—Right (a) and left (b) mastoid processes of Lee Harvey Oswald as photographed on 4 Oct. 1981. Note the evidence of prior mastoid surgery in b. (Autemortem records of left mastoidectomy noted on military enlistment and separation medical records in October 1956 and September 1959, respectively.)

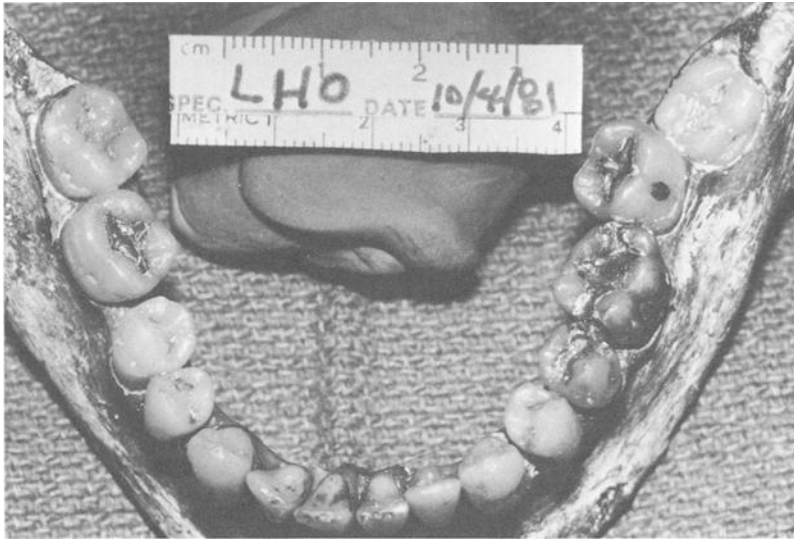


FIG. 3—The dentition of Lee Harvey Oswald as photographed on 4 Oct. 1981: mandibular teeth: occlusal view.

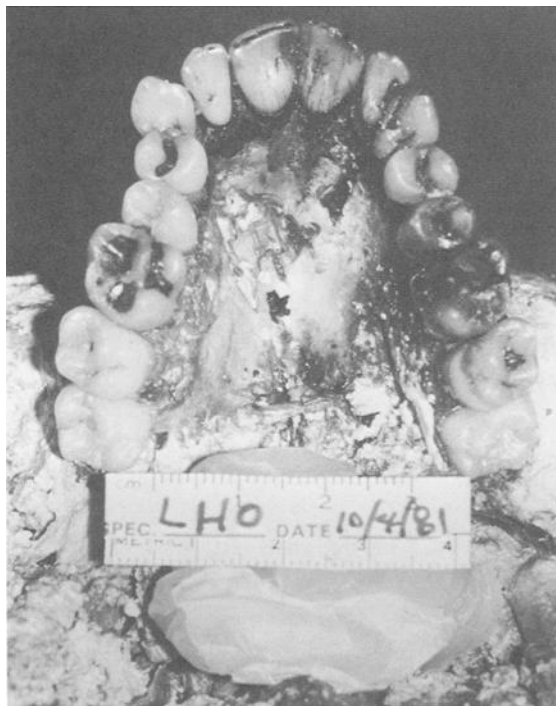
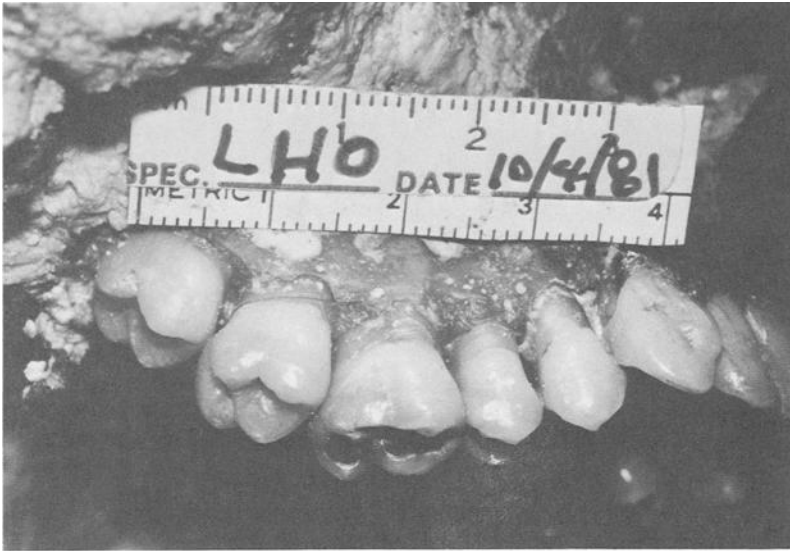
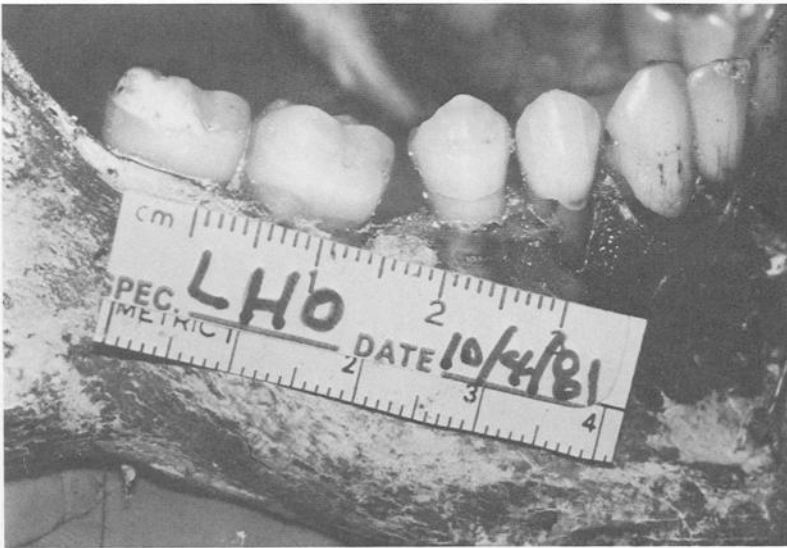FIG. 4—The dentition of Lee Harvey Oswald as photographed on 4 Oct. 1981: maxillary teeth: occlusal view.



a



b

FIG. 5—The dentition of Lee Harvey Oswald as photographed on 4 Oct. 1981: (a) maxillary right quadrant and (b) mandibular right quadrant.

Recruit Depot in San Diego on 25 Oct. 1956. Dental radiographs were made on that date and also on 27 March 1958 (No. 3, Table 4). The teeth indicated as carious and restored by Oswald's dental health records were compatible with radiographs made on 27 March 1958.

The second question was whether or not all inconsistencies in the dental records could be explained and the records documented as being authentic. Charting errors are common, especially in a dental health record that has entries by many different practitioners as in the mili-

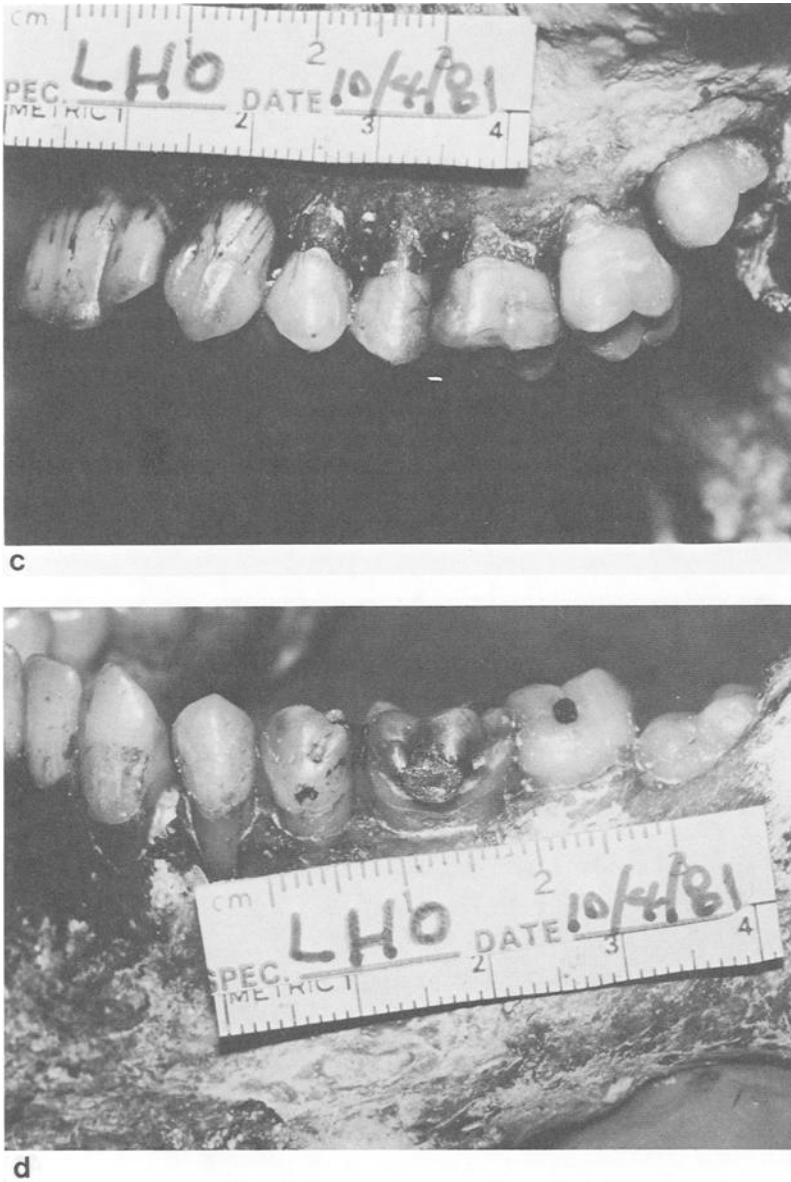
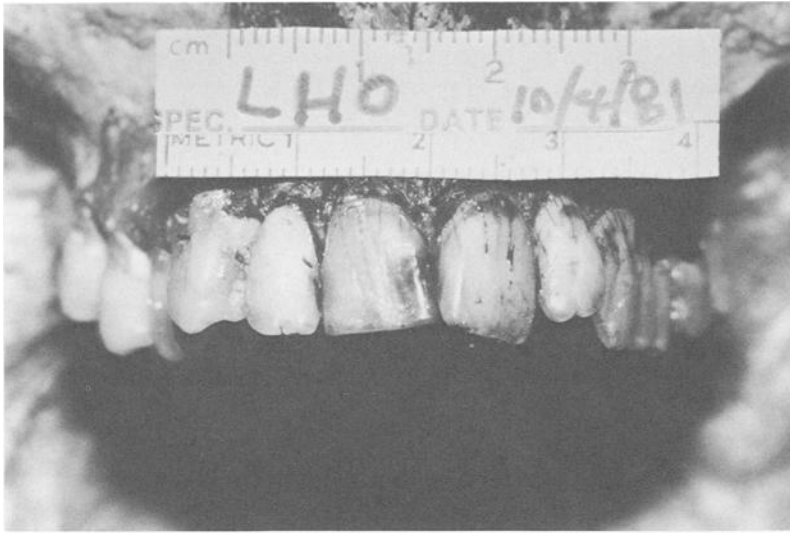


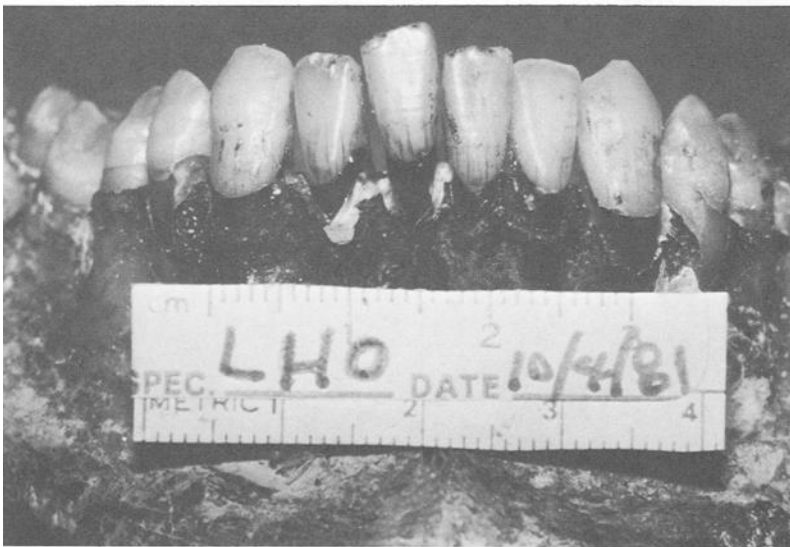FIG. 5—The dentition of Lee Harvey Oswald as photographed on 4 Oct. 1981: (c) maxillary left quadrant and (d) mandibular left quadrant.

tary. The Forensic Dental Examination Summary (Table 3) indicates that the following errors were found and explainable:

1. Maxillary right third molar (No. 1, Universal System)
Tooth noted as missing on several examinations and radiographs was actually unerupted and is not normally found in the radiographic view used.
2. Maxillary right second molar (No. 2, Universal System)



e



f

FIG. 5—The dentition of Lee Harvey Oswald as photographed on 4 Oct. 1981: (e) maxillary anterior teeth and (f) mandibular anterior teeth.

Occlusal-lingual metallic restoration incorrectly charted on 25 Oct. 1956 which was really occlusal caries as documented on radiographs of 27 March 1958. Occlusal-lingual metallic restoration also was confused with the same restoration in the adjacent tooth (maxillary right first molar).

- 3. Maxillary left first premolar (No. 12, Universal System)
- Maxillary left second premolar (No. 13, Universal System)
- Maxillary left first molar (No. 14, Universal System)

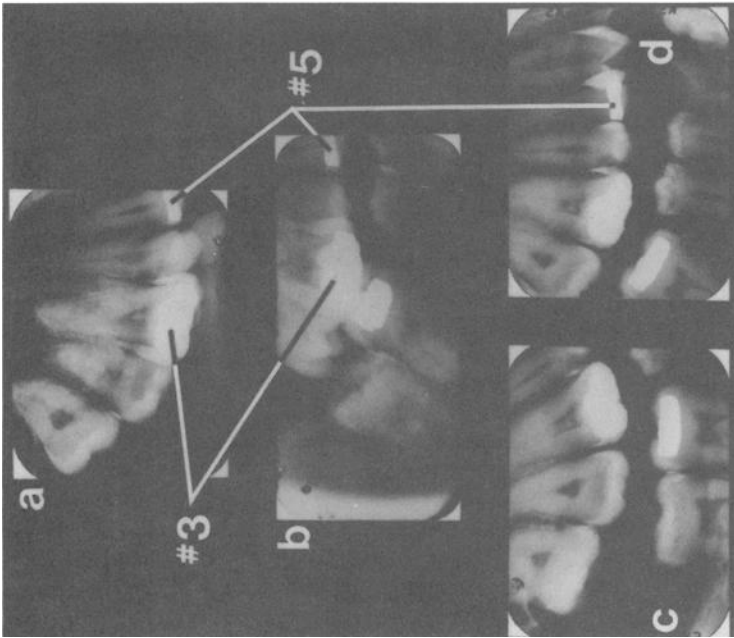


FIG. 6.—The postmortem and antemortem dental radiographs of the right maxilla and mandible of Lee Harvey Oswald: (a, b, and d) postmortem radiographs, 4 Oct. 1981 and (b) antemortem radiograph, 27 March 1958. No. 3 Maxillary right first molar—restorations demonstrate more similar radiographic morphology when antemortem duplication (b) is duplicated in (a) versus that in (c) and (d). No. 5 Maxillary right first premolar—restoration demonstrates identical radiographic morphology in all radiographs.

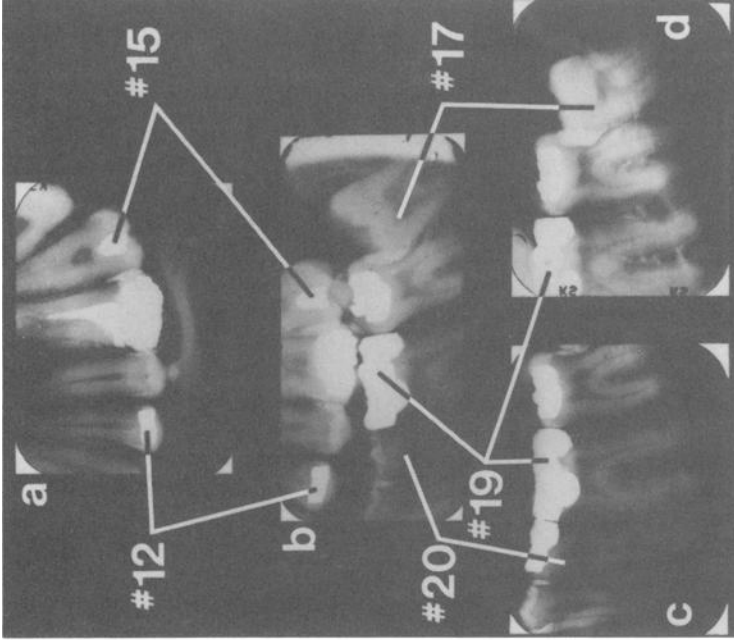


FIG. 7.—The postmortem and antemortem dental radiographs of Lee Harvey Oswald of the left maxilla and mandible: (a, c, and d) postmortem radiographs, 4 Oct. 1981 and (b) antemortem radiograph, 27 March 1958. No. 12 Maxillary left first premolar—restoration demonstrates identical radiographic morphology in all radiographs. No. 15 Maxillary left second molar—restoration demonstrates identical radiographic morphology in all radiographs. No. 17 Mandibular left third molar—antemortem angulation (b) is duplicated in (d) resulting in similar tooth contacts in postmortem radiographs. No. 19 Mandibular left first molar—restorations demonstrate similar radiographic morphology in (b) (antemortem) and (c) and (d) (postmortem). No. 20 Mandibular left second premolar—similar pulpal anatomy in (b) (antemortem) and (c) (postmortem).

Compound error involving charting on 27 March 1958 of: (1) interproximal restorations versus caries and (2) one tooth anterior in the arch than correct (that is, on adjacent contact areas of No. 12 and No. 13 versus No. 13 and No. 14) which is correctly documented on the radiographs of the same date.

4. Maxillary left third molar (No. 16, Universal System)

Same error as maxillary right third molar described above.

After much study of the dental records, it was decided independently by each team member that the dental records were authentic and could be used to support an identification made from the dentition. Figures 6 and 7 demonstrate the high degree of consistency between the antemortem and postmortem radiographs. Identical radiographic morphology was obtained when comparing both sets of radiographs in the maxillary right first premolar (No. 5), the maxillary left first premolar (No. 12), and the maxillary left second molar (No. 15); and similar radiographic morphology was demonstrated in the maxillary right first molar (No. 3), the maxillary left first molar (No. 14), and the mandibular left third molar (No. 17). (The Universal Tooth Numbering System was used.) Additionally, similar pulpal anatomy was demonstrated between antemortem and postmortem radiographs in the mandibular left second premolar (No. 20).

Based upon the consistency of the dental charting, the dental radiographs, the dental records, and the lack of any unexplainable, inconsistent items, positive dental identification was made.

Summary and Conclusion

A news conference was held at approximately 3:00 pm (CDT) on 4 Oct. 1981, at Baylor Medical Center for the examination team to announce that based upon the forensic science ex-

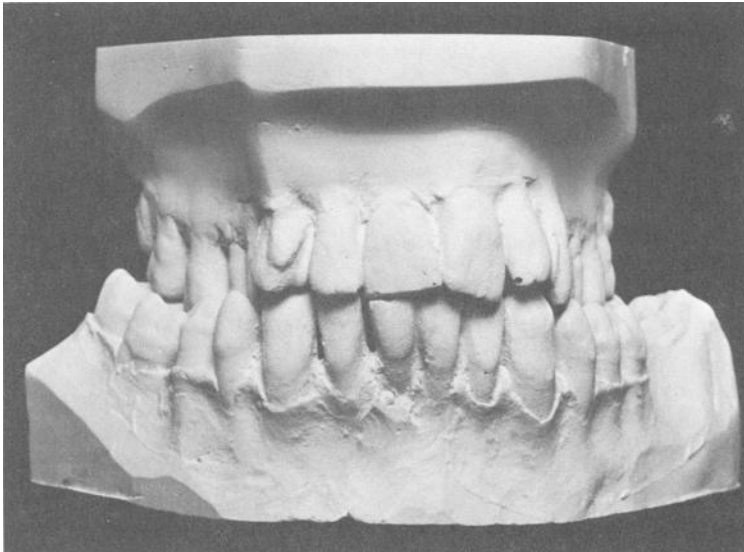


FIG. 8—Dental stone casts of Lee Harvey Oswald made on 4 Oct. 1981. Note the bilateral crossbite and the rotation of the maxillary left central incisor.

UPPER LEFT		LOWER LEFT	
partially erupted	16		17 partially erupted
occlusal amalgam	15		18 occlusal amalgam facial amalgam
mesial-occlusal amalgam, root canal therapy, fractured mesial-lingual cusp	14		19 mesial-occlusal- distal amalgam; facial amalgam
distal caries	13		20 distal-occlusal amalgam
occlusal amalgam	12		21 normal
normal	11		22 normal
distal amalgam	10		23 normal
distal rotation	9		24 normal
mesial caries distal rotation	8		25 normal
normal	7		26 normal
prominent facial tubercule	6		27 normal
occlusal amalgam	5		28 normal
distal caries	4		29 normal
mesial & distal pit occlusal restorations; occlusal-lingual amalgam	3		30 Old extraction site
occlusal caries	2		31 occlusal amalgam mesial drift
partially erupted	1		32 mesial drift
UPPER RIGHT		LOWER RIGHT	

FIG. 9—Composite postmortem dental charting of Lee Harvey Oswald made by Drs. Cottone and Sopher on 4 Oct. 1981 (Universal Tooth Numbering System).

amination conducted that date, “the remains in the grave marked as Lee Harvey Oswald are indeed Lee Harvey Oswald.” This conclusion was based upon comparison of the postmortem dental findings with existing antemortem dental charts and radiographs. The left mastoidectomy defect also correlated with the antemortem medical records.

Acknowledgment

Special notes of appreciation to the Photography Unit of the University of Texas Health Science Center at San Antonio for the security measures employed while developing and print-

TABLE 3—Forensic dental examination summary of Lee Harvey Oswald, 4 Oct. 1961.

Tooth Number ^a	Tooth Name	Antemortem			Postmortem			Correlation
		Finding	Source ^b	Remarks	Charting	Radiographs	Remarks	
1	maxillary right third molar	missing	2, 3, 4		partially erupted	partially erupted	tooth unerupted at time of antemortem exam and radiographs	consistent
		not visible	5	radiographs do not show maxillary bone				
2	maxillary right second molar	occlusal lingual metallic restoration	2	10/25/56	occlusal caries	occlusal caries	error in charting; should have been marked on Tooth 3	probably consistent
		normal	5	3/27/58			caries between 1958 and 1963	
3	maxillary right first molar	occlusal lingual metallic restoration	2, 5		occlusal lingual amalgam restoration	large occlusal restoration	restorations show similar radiographic morphology	consistent
		normal	5	3/27/58			restorations completed after last antemortem records	
4	maxillary right second molar	normal	5	3/27/58	distal caries	distal caries	new caries developed between 1958 and 1963	consistent
		occlusal lingual metallic restoration	2, 5	...	occlusal amalgam restoration	occlusal metallic restoration	restorations show identical radiographic morphology	
6	maxillary right cuspid	normal	prominent facial tubercule

8	maxillary right central incisor	normal	rotated distally	...	consistent
9	maxillary left central incisor	rotated	2	10/25/56	mesial caries rotated distally	mesial caries	consistent
10	maxillary left lateral incisor	distal amalgam restoration	2, 3	5/14/58	distal amalgam restoration	...	consistent
12	maxillary left first premolar	occlusal metallic restoration	2	10/25/56	occlusal amalgam restoration	occlusal metallic restoration	restorations show identical radiographic morphology
13	maxillary left second premolar	distal restoration	3	no date	no distal restoration	no distal restoration	error in charting; should have been distal caries 13
		mesial restoration	3	no date	no mesial restoration	no mesial restoration	error in charting; should have been mesial caries 14
14	maxillary left first molar	distal caries occlusal lingual metallic restoration	S	3/27/58	mesial occlusal amalgam restoration with broken mesial lingual cusp	distal caries mesial occlusal restoration with broken mesial lingual cusp	root canal therapy and restoration performed after last antemortem dental record date
15	maxillary left second molar	occlusal metallic restoration	2, 5	...	mesial fossa amalgam restoration	mesial fossa metallic restoration	restorations show identical radiographic morphology
16	maxillary left third molar	missing	2, 3, 4		partially erupted	partially erupted	tooth unerupted at time of antemortem exams and radiographs
		not visible	S				radiographs do not show maxillary bone

TABLE 3—Forensic dental examination summary of Lee Harvey Oswald, 4 Oct. 1981.

Tooth Number ^a	Tooth Name	Antemortem		Postmortem		Correlation		
		Finding	Source ^b	Remarks	Charting		Radiographs	Remarks
17	mandibular left third molar	missing/im-pacted	2, 3, 4		partially erupted	partially erupted	...	consistent
		unerupted occlusal metallic restoration	5 2	3/27/58 10/25/56	occlusal amalgam restoration	occlusal metallic restoration		...
19	mandibular left first molar	facial amalgam restoration	2	11/1/56	facial amalgam restoration			
		occlusal metallic restoration	2	10/25/56	mesial occlusal distal amalgam restoration	mesial occlusal distal metallic restoration		restorations show similar radiographic morphology
20	mandibular left second premolar	mesial occlusal distal amalgam restoration	2, 5	11/1/56 3/28/58				
		facial amalgam restoration	2	11/1/56	facial amalgam restoration			
21-29		distal occlusal amalgam restoration	2, 3	4/30/58	distal occlusal metallic restoration	distal occlusal metallic restoration	...	consistent
		distal caries normal	5 ...	3/28/58 ...	normal		...	several mm lingual bone loss 24 and 25
30	mandibular right first molar	missing	2, 3, 4, 5	...	missing	missing	...	consistent

31	mandibular right second molar	occlusal metallic restoration with mesial drift	2, 5	...	occlusal amal- gam restoration with mesial drift	occlusal metallic restoration with mesial drift	...	consistent
32	mandibular right third molar	missing/ unerupted	2, 3, 5	...	mesial drift	present	...	consistent
		present	4	tooth partially erupted at time of charting				
Other	...	bilateral posterior crossbite	2	10/25/56	bilateral posterior crossbite	consistent
		exam and bite- wing radio- graphs	3	3/27/58				consistent

^aUniversal Number System.

^bFrom list of Antemortem Dental Records (Table 4).

TABLE 4—*Lee Harvey Oswald's antemortem dental records available on 4 Oct. 1981.*

-
1. Report of medical examination on Military Standard Form 88 (enlistment exam) completed at Armed Forces Examination Station, Dallas, TX, on 24 Oct. 1956 (dental exam not performed).
 2. Dental Health Record on Military Standard Form 603. Initial exam completed at Marine Corps Recruit Depot, San Diego, CA, on 25 Oct. 1956 with services rendered through 14 May 1958.
 3. Dental examination and treatment record on NAVMED-1299 initially completed on 27 March 1958 with operations and treatments through 14 May 1958.
 4. Report on medical examination on Military Standard Form 88 (separation exam) completed at U.S. Marine Corps Air Station El Toro, Santa Ana, CA on 3 Sept. 1959.
 5. Dental interproximal (bitewing) radiographs made at U.S. Marine Corps Air Station El Toro, Santa Ana, CA on 27 March 1958.
-

ing the illustrations along with Felix Cordero, Jr. and Hamo Meguerditchian for their help with the examination.

References

- [1] Eddowes, M., *The Oswald File*, Clarkson N. Potter, New York, 1977.
[2] *Eddowes v. Curry*, Tex. Civ. App. 599 SW2d 367.

Address requests for reprints to
James A. Cottone, DMD, MS
Department of Dental Diagnostic Science
The University of Texas Health Science
Center at San Antonio Dental School
7703 Floyd Curl Dr.
San Antonio, TX 78284